

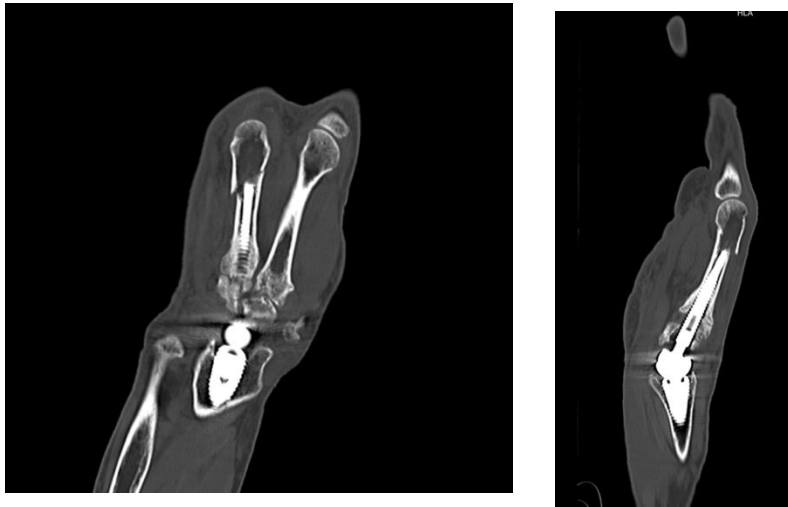
POSTTRAUMATIC METACARPAL FRACTURES AFTER UNCEMENTED MOTEC® TOTAL WRIST ARTHROPLASTY: A CASE REPORT

Gregoire N. Chick, MD PhD ^{1,2,3}, Laurène Niederhauser ¹

¹ Hand and Wrist Unit, Genolier Campus, Switzerland; ² Ghent university, Ghent, Belgium; ³ Weil Cornell University, NY, USA

HYPOTHESIS

Posttraumatic third metacarpal fracture following **uncemented MOTEC® total wrist arthroplasty (TWA)** present unique challenges due to limited space for internal fixation.



Ensuring solid internal fixation and initiating early rehabilitation can reduce secondary stiffness and maintain wrist prosthesis function.

MARCH 24-28, 2025.WASHINGTON, D.C., USA. IFSSH/IFSHT

The Motec® TWA is **Cementless, Modular** prosthesis with a Spherical joint

Ball-and-socket design, with ceramic coated CoCrMo radius Cup, head and neck (**Metal/Metal friction**)

Threaded stems are used to achieve immediate primary fixation in the cortical bone at two-thirds of the proximal length.

Coating stems with **Bonit®** enables long-term implant fixation and osseous integration.

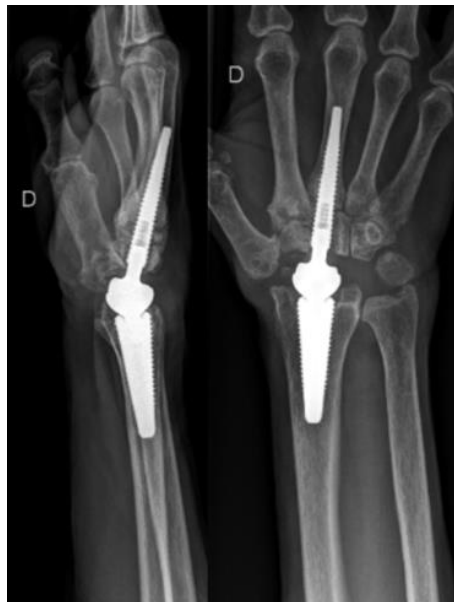

MARCH 24-28, 2025.WASHINGTON, D.C., USA. IFSSH/IFSHT

METHODS

A 65-year-old right-handed nurse presented with a fall-induced injury to her right hand two years post-MOTEC® TWA, initially performed after a failed proximal row carpectomy.

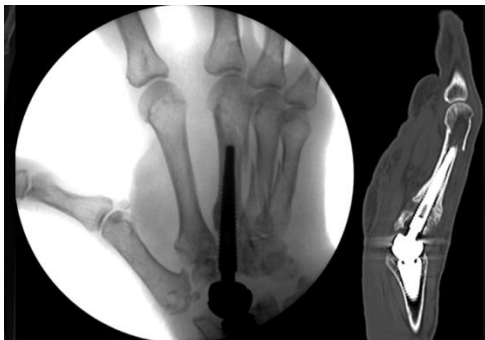She experienced pain relief, improved range of motion, and enhanced grip strength at her two-year follow-up prior to the injury.



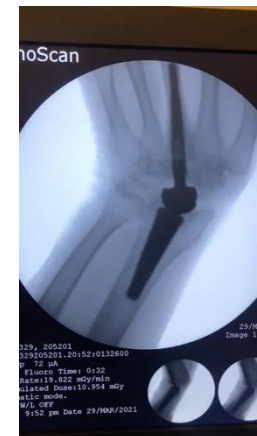*Lateral and AP X-rays
Motec, 3 weeks post-TWA
implantation*

Radiological imaging showed 3rd, 4th and 5th metacarpals oblique fractures

The fracture on the third metacarpal was aligned with the distal end of the stem.



*Fluoroscopic AP image and sagittal CT-scan showing metacarpal
fractures (2 years post-TWA implantation)*

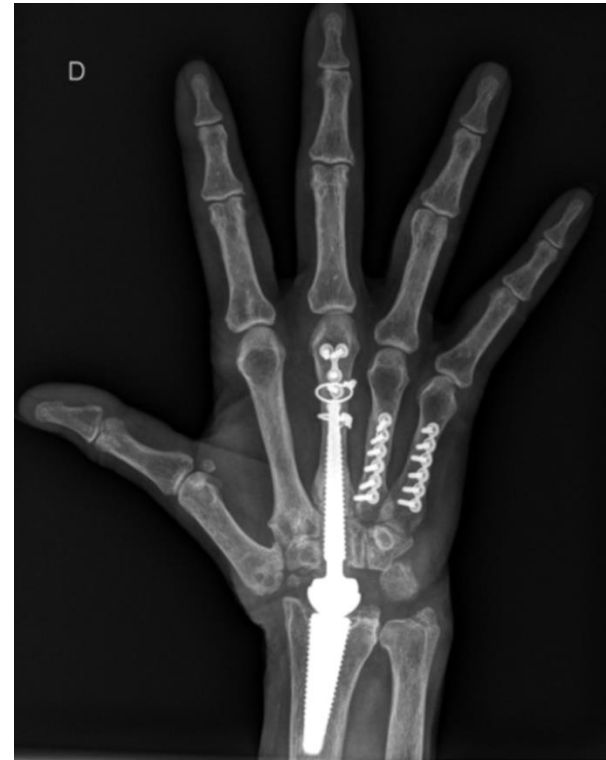

At 2-year follow-up: clinical
evaluation and dynamic
fluoroscopy .

INTERNAL FIXATION & REHABILITATION

The 3rd metacarpal internal fixation was achieved using a **dorsal locking T-plate 2.0 and 1.0 wire cerclages** at the distal epiphysis, ensured securing attachment to the diaphysis, providing solid fixation without malrotation.

Immediate rehabilitation was initiated, with buddy taping and a four-week protective wrist-free splint followed by a two-week night splint.



*Postoperative AP radiographs of the 3rd, 4th and 5th metacarpal fracture secured with plates
Internal fixation of the third metacarpal was limited by the restricted space available due to the stem prosthesis.*

RESULTS

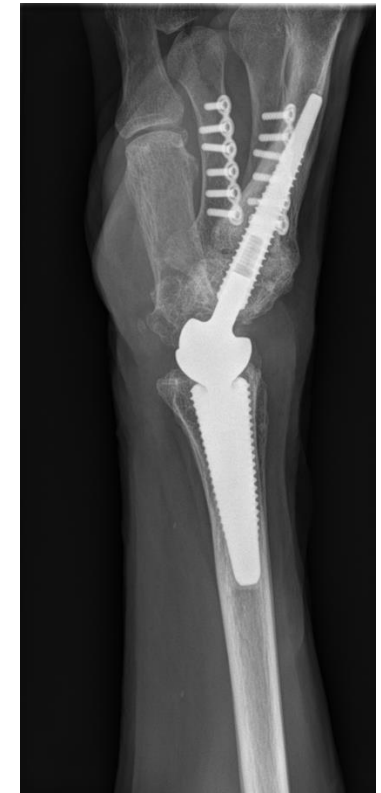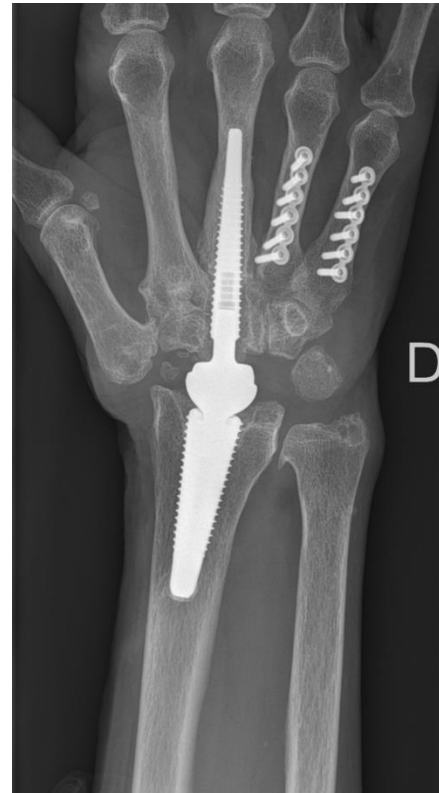Bony fusion was achieved at three months

Hardware removed seven months later

At the two-year follow-up, wrist was pain-free, with full stable third metacarpophalangeal joint motion (110/0°).

Wrist flexion: 80°, Extension: 50°, Radial deviation: 20°, Ulnar deviation: 40°.

Grip strength: 20 kg.



*At the last followup
+ 5 years post- TWA implantation
+ 33 months post- third metacarpal fracture*

Post-op	Flexion	Extension	Ulnar deviation	Radial deviation	Grip strength
6 months	60	40	20	30	19Kg
1 year	75	60	30	30	22Kg
2 years (before the injury)	80	60	30	30	20Kg
4 years (+ 2 from the injury)	80	60	40	40	20,5Kg

SUMMARY POINTS

- Posttraumatic metacarpal fractures near the stem prosthesis present a technical challenge for internal fixation due to limited space.
- Solid internal fixation and immediate rehabilitation are crucial to prevent secondary stiffness and protect the wrist prosthesis.
- This case demonstrated successful internal fixation using a locking T-plate and wire cerclages, with positive long-term outcomes including stable, pain-free wrist function and satisfactory joint motion.

Replacing the stem with a longer one would have been an alternative, knowing that the change required a weakening longitudinal corticotomy when the implant is fully integrated.

References:

- Reigstad O et al. Promising one- to six-year results with the Motec wrist arthroplasty in patients with post-traumatic osteoarthritis. J Bone Joint Surg Br. 2012 Nov;94(11):1540-5.
- Giwa L, Siddiqui A, Packer G. Motec Wrist Arthroplasty: 4 Years of Promising Results. J Hand Surg Asian Pac Vol. 2018 Sep;23(3):364-368.
- Lenz M, Lehmann W, Wähnert D. Periprosthetic fracture fixation in osteoporotic bone. Injury. 2016 Jun;47 Suppl 2:S44-50.

The authors declared no potential conflicts of interest with respect to the research, authorship and/or publication of this presentation.

MARCH 24-28, 2025.WASHINGTON, D.C., USA. IFSSH/IFSHT